

A Rare Case of Pulmonary Embolism: A Case Report

Tirtha Man Shrestha,¹ Ram Neupane,¹ Bandana Neupane,¹ Reeru Manandhar²

¹Department of General Practice and Emergency Medicine, Tribhuvan University Teaching Hospital,

²Sahid Gagalal National Heart Center

ABSTRACT

Pulmonary embolism in an old patient with a history of coagulation disorder, any recent major surgeries or in a chronic heart or lung diseases is widely reported. Also, a recent history of travel by air with flight distance of more than 5000km or BMI greater than 35 kg/m² increase risk. However, we report here, a suggestive case of acute pulmonary embolism in a previously well male of 38 years, with a BMI of 25.71kg/m² without any history of chronic illness or acute exacerbations.

The patient presented in health facility with sudden onset of radiating chest pain and some other non-specific symptoms. Neither any other significant personal risk factors except smoking, nor any family history of heart/lung diseases were ruled out during initial assessments. On investigations, other routine examinations were normal but T-wave inversion was noticed in lead V1-4 in ECG, Troponin-I was positive and CPK-MB was slightly elevated (27 U/L). Furthermore, no any remarkable changes were noticed in Chest X-ray. Then, the patient was referred to higher center with cardiac facility with provisional diagnosis of Acute Coronary Syndrome for further evaluation and management.

Thereupon, Coronary Angiogram (CAG) was done and the report was normal but echocardiography findings were suggestive of pulmonary Embolism. D-dimer was also elevated (8279.05 ng/ml) but venous doppler study of bilateral lower limb was normal. Finally, CT-PA showed partially occluding thrombus in main pulmonary bifurcation extending into left and right pulmonary artery, its bilateral segmental branches and calcified granuloma was seen in right lobe of liver. Patient was under inj. LMWH and other supportive management during hospitalization. After an uneventful hospital stay for 12 days, general condition was improved and eventually, patient was discharged, with oral warfarin.

Keywords: chest pain; Nepal; pulmonary embolism; risk factors.

INTRODUCTION

Pulmonary Embolism (PE) is one of the common and highly fatal cardiovascular disorder.¹⁻³ On top of that, despite of advances in study of medicine, diagnostic techniques and treatment, most of the cases are still diagnosed late or missed and often revealed later after death during forensic investigation.^{2,4-6} Once the case goes undiagnosed, the mortality is said to be increased by ⁴⁻⁶ folds in comparison to those

cases that are diagnosed early. In this scenario, early suspicion and timely diagnosis has been crucial in significant reduction of morbidity and mortality in pulmonary embolism.^{2,7}

Often, pulmonary embolism occurs in patient with age over 60 years, history of venous thromboembolism, coagulation disorders and critically ill or debilitated patients. Any recent history of long distance (>5000km) air travel, major surgeries, malignancies, or respiratory or heart failure increase risk.^{1,3-5,8} PE is attributed to smoking, obesity and use of oral contraceptives. ⁹ At most, 45% of proven PE cases also have DVT.^{2,9,10} Patients experience

Correspondance:

Tirtha Man Shrestha,

General Practice and Emergency Medicine, TUTH

Email: tirtha_48@yahoo.com, Phone: +977-9851017345

dyspnea (sudden on-set) in more than 85% of cases, sharp chest pain mimicking cardiac cause in 50%, syncope in more than 14% and cough in one-fifth of cases with occasional hemoptysis.^{2,4,6,7}

Dyspnea, during exacerbation among chronic patients with cardiac or respiratory diseases, can be a stand-alone presentation in some cases of PE in absence of chest pain. Eventually, such cases could face diagnostic delays due to lack of suspicion. Similarly, ischemic changes can occur simultaneously with underlying PE during severe chest pain. In such cases, PE can co-exist with cardiac disorder. All in all, PE could be one among three vascular triad (the other two: acute coronary syndrome and acute aortic dissection), usually seen in non-traumatic emergencies of thorax.^{4,11,12}

However, PE at times, could also present asymptotically (40% - 50% of cases with Deep Vein Thrombosis) and are recorded in an earlier age.¹³ It is said that 30% of PE cases are of idiopathic in nature. Although, a number of non-specific tools are used from: ECG, Chest X-Ray, D-dimer, cardiac markers to the initial physical assessment, the role of suspicion from health care providers is high in PE along with use of Computed Tomography and Angiogram in order to confirm the suspected cases. There are reports of PE-cases, where routine tests were normal. Therefore, suspicion has now been an important index for early diagnosis of such cases.^{2,3,7,14} Here, we present a rare case of PE that would have been missed if a possibility of PE was not considered, then and there.

CASE REPORT

A 38-year-old, previously well Asian male with habit of smoking, presented in health facility, with sudden onset of radiating chest pain followed by syncope. The event was experienced by the patient, before an hour of arrival. On examination, patient was anxious with PR 80 beats/min, RR 24 breaths/min, SPO2 of 87% (in room air) with a record of low BP (90/50 mm of Hg) and GRBS

238 mg/dl. The body temperature was normal and other gross physical examination findings were insignificant. There was no any history of hypertension, DVT or any chronic illness in patient as well as in family.

On routine blood examination, except a slight increase in random blood sugar level and WBC/TLC of 16,000/ cu mm, other findings were normal. Later, T wave inversion in lead v1, v2, v3 and v4 was noticed in ECG.

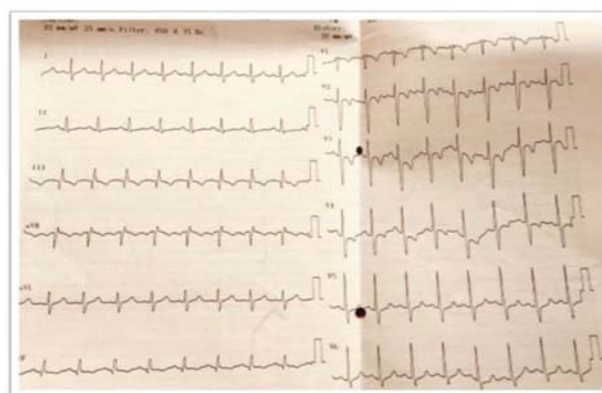


Figure 1. ECG of the patient [10 mm/mV, 25 mm/S]; showing Sinus Rhythm, 78bpm with small S wave in lead I, a Q wave with T wave inversion in lead III and a T wave inversion in lead V1 to V4.

On subsequent enzyme examination, CPK-MB was 27 U/L and Troponin-I was positive. No any other significant findings were seen in Chest-X-ray. Hence, patient was referred to a higher center with cardiac facility with provisional diagnosis of Acute Coronary Syndrome for further evaluation and management. Patient was managed conservatively and subjected for Coronary Angiography. CAG was normal; however, Pulmonary Embolism was suspected on the basis of Echocardiographic findings of Acute Cor-pulmonale (Grade 1 LV Diastolic Dysfunction, Mildly Dilated Right and Left Ventricle, Mild to Moderate TR and Moderate PAH -50 mm of Hg). Then, D-dimer test was done and found to be elevated (8279.05 ng/ml). However, there was no evidence of DVT as Venous Doppler study of bilateral lower limb was normal. However, the patient was sent to near-by facility for CT-PA test in the evening.

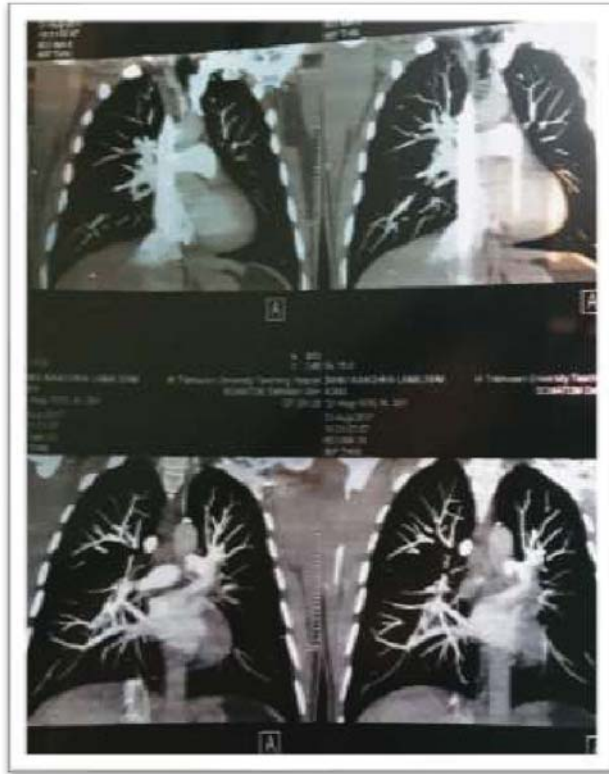


FIGURE 2. CTPA OF THE PATIENT CORONAL VIEW.

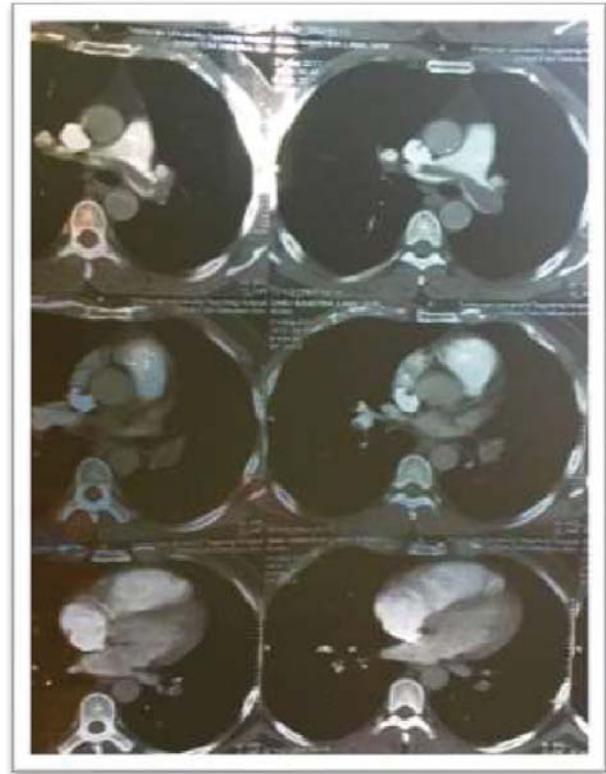


FIGURE 3. CTPA OF THE PATIENT/AXIAL VIEW.

CT-PA report was suggestive of partially occluding thrombus in main pulmonary bifurcation extending into left and right pulmonary artery and its bilateral segmental branches, suggestive of Acute Pulmonary Embolism. Report also mentioned small pleural based consolidation in bilateral lower lobes as well as calcified granuloma in right lobe of liver.

Patient was under Inj. LMWH, Inj. Ofloxacin and other supportive measures during admission. After an uneventful hospital stay, patient was discharged on 12th day of hospitalization with oral warfarin. GC was fair and vital signs were near normal: Pulse 58b/m, BP 100/70mm of Hg, RR 20/min. There were no any ST changes and arrhythmia in ECG. Patient was advised to follow-up after one week in Medicine-OPD with HbA1c and Fasting/PP Blood-Sugar reports.

DISCUSSION

Pulmonary Embolism at this age without any significant risk factors is a rare presentation. Normally PE occurs after the age of 60. However, sometimes, PE is noticed at the very young age, that develops together with other medical/surgical or congenital conditions like sickle cell trait,

DVT or carcinomas.^{1,3,8,9,15} However, literatures reporting on development of PE in a previously well patient, at the age of 38 is rare.

Patient experienced those symptoms, while sitting at home, i.e. there was no any correlation with air travel or flight distance in this patient, that often matters in PE.^{8,9} The risk of developing PE is higher in smokers than in non-smokers. Also, one having BMI greater than 35kg/m² are at increased risk.⁹ For this, the patient presented here, was a smoker but with a BMI of 25.71kg/m².

The patient was dyspneic, tachypneic and the BP was low. The chest pain was sharp and radiating with sudden onset followed by syncope, mimicking the cardiac cause. Similar symptoms were reported in other PE cases.^{2,7,9}

T wave inversion in leads V1-4 is also common in PE. DVT, however, may not be demonstrable in 52% of PE cases, which was negative in this case, too.^{5,7,9} Increase in blood sugar level was newly noticed in this patient without any previous personal or family history. Changes in ECG and positive Troponin test guided Echocardiography and Coronary Angiogram (CAG) in this patient. Once, symptoms of Right Heart Failure were noticed in Echo with normal CAG, suspicion of PE was increased.

Although not a specific diagnostic test for PE, elevated D-dimer as seen in this case, is commonly reported in a no. of other PE cases as well.⁹ A study however, reported normal D-dimer but elevated APTT in a young PE case.¹³ Literatures mentioned that, elevated D-dimer alone, could not distinguish PE from that of non-PE cases, but could still be useful in guiding further treatment strategy due to its high negative-predictive value.^{12,16} The patient later, underwent a CT-PA test (gold standard test for PE), and PE was confirmed.

As reported, initiation of anticoagulant in a young case of PE with history of DVT, resulted development of multiple thrombi and the case died of respiratory.¹³ However, the patient presented here was under Inj. LMWH, the entire hospital stay was uneventful and later discharged with oral warfarin.

ACKNOWLEDGEMENTS

The authors thank the patient for giving consent to use the data for publication. The direct or indirect contribution made by the emergency and other involved departments including laboratory and radiology is highly acknowledged by the authors.

CONFLICT OF INTEREST: None.

CONSENT: Case Report Consent Form was signed by the patient and is attached.

REFERENCES

1. Khakural P, Shrestha KR, Sapkota R, Shrestha UK. An Unusual Case of Pulmonary Embolism. *J Surg Case Rep*. 2015 Feb 15;2015(2). Crossref
2. Belohlavek J, Dytrych V, Linhart A. Pulmonary embolism, part I: Epidemiology, risk factors and risk stratification, pathophysiology, clinical presentation, diagnosis and nonthrombotic pulmonary embolism. *Exp Clin Cardiol*. 2013 Spring;18(2):129–138. Crossref
3. Hashmani S, Tipoo Sultan FA, Kazmi M, Yasmeen A. Massive pulmonary embolism presenting as seizures. *J Pak Med Assoc*. 2016 Dec;66(12):1656–1658. Crossref
4. Walen S, Damoiseaux RA, Uil SM, van den Berg JW. Diagnostic delay of pulmonary embolism in primary and secondary care: a retrospective cohort study. *Br J Gen Pract*. 2016 Jun;66(647):e444-50.
5. Kukla, P. et al. Correlations etween Electrocardiogram and Biomarkers in Acute Pulmonary Embolism: Analysis of ZATPOL-2 Registry. *Ann. Noninvasive Electrocardiol*. 22, e12439 (2017). Crossref
6. Rauniyar B, Adhikari CM, Rajbhandari R, et al. Observational Study of Pulmonary Embolism Patients in Shahid Gangalal National Heart Centre. *NHJ*. 2010;7(1):25–28. Crossref
7. Adhikari CM, Bishal KC, Khadka S. Clinical profile, management and outcome of pulmonary embolism in Shahid Gangalal National Heart Centre, Kathmandu, Nepal. *Egypt Hear J*. 2018;70(1):41–43. Crossref
8. Ellensen VS, Saeed S, Geisner T, Haaverstad R. Management of thromboembolism-in-transit with pulmonary embolism. *Echo Res Pract*. 2017 Dec;4(4):k47-k51. Crossref
9. Abdool K, Ramcharan K, Reyes AJ, Lutchman N, Alexander A. Bilateral Pulmonary Embolism after a Short-Haul Flight in a Man with Multiple Risk Factors including Sickle Cell Trait. *Case Rep Emerg Med*. 2017;2017:4316928. Crossref
10. Dumic I, Martin S, Salfiti N, Watson R, Alempijevic T. Deep Venous Thrombosis and Bilateral Pulmonary Embolism Revealing Silent Celiac Disease: Case Report and Review of the Literature. *Case Rep Gastrointest Med*. 2017;2017:5236918. Crossref
11. Hendriksen JM, Koster-van Ree M, Morgentern MJ, et al. Clinical characteristics associated with diagnostic

- delay of pulmonary embolism in primary care: a retrospective observational study. *BMJ Open*. 2017 Mar 9;7(3):e012789. Crossref
12. Stöger L, Schaefer-Prokop C, Geurts BH. Imaging of nontraumatic thoracic emergencies. *Curr Opin Pulm Med*. 2017 Mar;23(2):184–192. Crossref
13. Shah AY, Jamison M, Otero HJ, et al. A 17-Year-Old with Chest Pain. *Pediatrics*. 2017;139(3):e20160794. Crossref
14. Kukla P, Kosior DA, Tomaszewski A, et al. Correlations between electrocardiogram and biomarkers in acute pulmonary embolism: Analysis of ZATPOL-2 Registry. *Ann Noninvasive Electrocardiol*. 2017;22(4):e12439. Crossref
15. Shah, A. Y. et al. A 17-Year-Old with Chest Pain. *Pediatrics* 139, e20160794 (2017).
16. Tiruneh F, Awan A, Hunt N, et al. Correlation of Ventilation-Perfusion (V/Q) Scan Results as Compared with Clinical Probability of Pulmonary Embolism in African American Population. 2017 Jun 14;9(6):e1353. Crossref