

Unusual Presentation of Extruded Disc: A Case Report

Rajesh Pratap Shah,¹ Bishnu Babu Thapa,¹ Sujata Panta,² Kabita Birat Karmacharya³

¹Department of Orthopaedics, Shree Birendra Hospital, Chhauni, Kathmandu, Nepal, ²Department of Radiology, Shree Birendra Hospital, Chhauni, Kathmandu, Nepal, ³Department of Pathology, Shree Birendra Hospital, Chhauni, Kathmandu, Nepal.

ABSTRACT

A 38-year male presented with severe low back pain radiating towards right lower limb which was progressively increasing with decrease in motor power of the ipsilateral ankle dorsiflexion and toe extension. Magnetic Resonance study with gadolinium suggested dorsal epidural migration of the extruded disc at L4-L5 level compressing the thecal sac, which mimics the differential diagnosis epidural abscess, epidural hematoma, synovial cyst and extradural space-occupying lesion. Open lumbar discectomy was done, and the large, herniated disc was found dorsal to the thecal sac adhering dura mater, which was removed meticulously and the patient was symptomatically better postoperatively. The power of his lower limb gradually increased by physiotherapy in subsequent follow-up.

Keywords: back pain; dorsal disc extrusion; lumbar herniation; unusual presentation.

INTRODUCTION

Lumbar disc herniation is commonly confined to the anterior epidural space. Migration of the disc to the dorsal epidural space is very rare. Only a few cases with sequestered disc have been reported. We report a very unusual case of migration of extruded disc dorsal to the thecal sac in a 38-year-old male. We review the literature and discuss the difficulty in diagnosis of the extruded disc.

CASE REPORT

A 38-year-old male presented with a chief complaint of low back pain for six months. The pain was progressive in nature and radiating toward the right lower limb for three months. He was treated conservatively with oral analgesic and physiotherapy, but there was no improvement. The pain gradually increased with the listing of the body towards the left side. On clinical examination, his straight leg raise was 60 degree in both the lower limb, extensor hallucis longus and flexor hallucis longus was 3/5, hypoesthesia in L4 and L5 dermatomes and loss of ankle reflex in the right lower limb. His bowel and bladder habits were normal.

MRI showed a Rt. Posterolateral epidural lesion, measuring approximately 11 x 6.5 x 7 mm in CC x TR x AP axis, was noted at L4- L5 level. The lesion exhibited isointense signal intensity relative to intervertebral disc on both T1 and T2 weighted images and rim enhancement on gadolinium-enhanced T1 weighted

image (Figure 1A and 1B). There was a disruption of the outermost annulus of the adjacent disc with disc extrusion and a track like enhancement leading to right posterior epidural space up to the lesion. Laboratory report showed erythrocytes sedimentation rate of 10 and C-reactive protein negative while the rest of other blood parameters were normal.

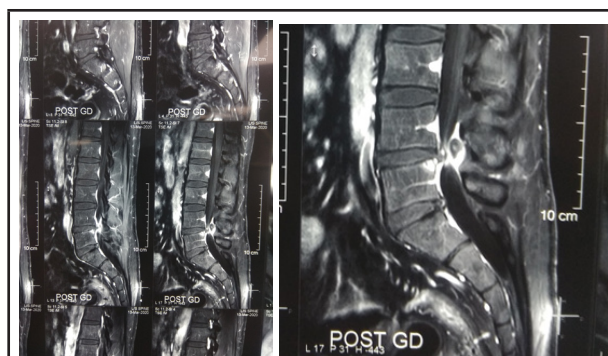

Figure 1A

Figure 1B

Figure 1. MRI of LS spine showing unusual disc protrusion at L4-L5- 1A: plane, 1B: contrast.

Open lumbar discectomy was performed at the L4-L5 level. Large disc material was removed from dorsal epidural space, which was compressing the thecal sac. (Figure 2). Histopathology report of the specimen

Correspondence: Dr. Rajesh Pratap Shah, Department of Orthopaedics, Shree Birendra Hospital, Chhauni, Kathmandu, Nepal. E-mail: roam2rajesh@gmail.com, Phone: +977-9841474819.

showed degenerated disc material with myxoid areas, adipocytes and blood vessels with no atypia or evidence of malignancy (Figure 3).

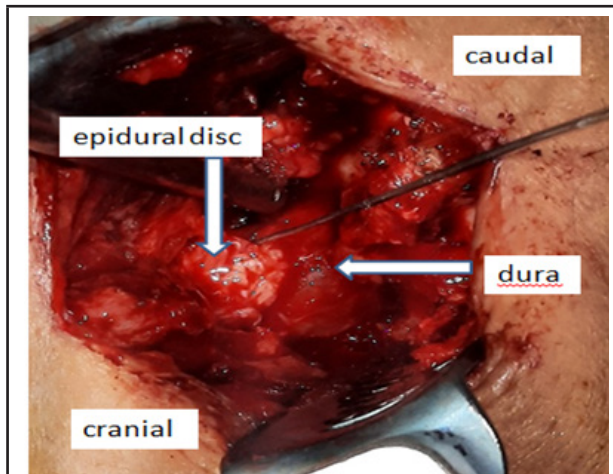


Figure 2. Open lumbar discectomy showing unusual extrusion of disc.

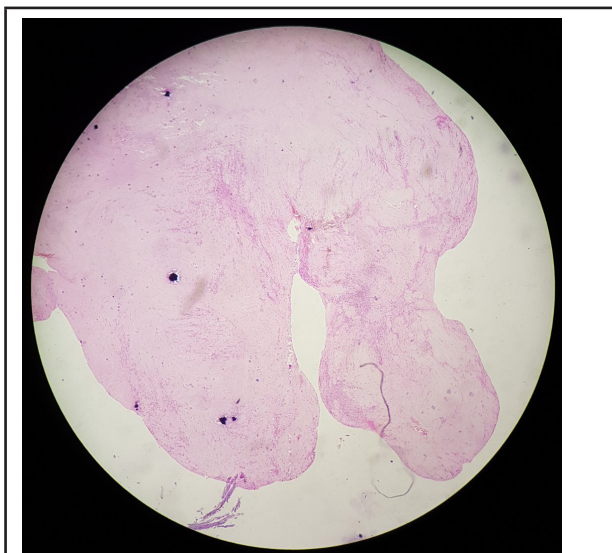

Figure 3. Histopathology of the extruded disc.

Postoperatively, the patient had relief from back pain and leg symptoms immediately after surgery. The patient was discharged and advised for physiotherapy. His stitches were removed two weeks after the surgery. There was complete recovery of the right lower limb's motor power and sensation during his three months follow up.

DISCUSSION

Lumbar disc herniation (LDH) is one of the commonest degenerative manifestations of the spine. It is of three types: Protrusion, Extrusion and Sequestration.^{1,2} Disc herniates posterolaterally or posteriorly into the spinal canal. Posterolateral herniation of the disc is the commonest presentation. It is because posteriorly,

there is a firm adherent of the posterior longitudinal ligament (PLL) to the periosteum of the vertebral body and the midline septum attaching PLL to the vertebral body hindering the posterior migration. The herniated disc migrates cranially in posterolateral herniation as there is a lack of deep fibres of PLL in the superolateral portion of the intervertebral disc, making more space available to accommodate the herniated disc. In contrast, it migrates caudally in posterior disc herniation. On posterior herniation, it enters into anterior epidural space (AES) by rupturing posterior longitudinal ligaments.^{3,4} However, larger disc fragment herniates into lateral extradural space through the free edge of PLL. It is rear for the herniated disc to reach dorsal epidural space⁵⁻⁹ as its migration is limited by a lateral membrane which is attached to PLL medially and wall of spinal canal laterally. Similarly, other structures limiting the dorsal migration of disc in the spinal canal are medial and lateral Dural ligament of Hoffmann, epidural vessel, spinal nerve root, Dura and fat.^{5,10} If there is a failure of any of these structures, the sequestered disc may migrate dorsally to the thecal sac. There are a few case report stating dorsal epidural migration of sequestered disc.^{5,7-10} In our case, the extruded disc has reached dorsal epidural space, which is extremely rare. Only one case of dorsal epidural migration of extruded disc has been reported till now in our knowledge, the other being migration of sequestered disc.¹⁰ This could be due to subligamentous migration of extruded disc anterior to PLL following the path of least resistance laterally to reach the dorsal epidural space as found preoperatively in our case.

MRI is the investigation of choice for herniated disc and gadolinium enhancement for extruded or sequestered disc showing peripheral rim enhancement due to neovascularization around the sequestered disc.^{11,12} The differential diagnosis could be a synovial cyst which is related to facet joint, epidural abscess shows the mass effect with hypointense on T1 and hyperintense on T2, tumor doesn't have rim enhancement.^{10,13} This patient had no constitutional symptoms, and his blood parameters were within the normal limit.

In our case, the disc was extruded at the level of L4-L5 and migrated all the way to dorsal epidural space as suggested in MRI. Gadolinium scan suggested rim enhancement due to neovascularization around the extruded disc suggested by the histopathology report (Figure 3). This type of rare dorsal epidural herniation of the extruded disc could be in case of heavy manual labor, traction therapy for the prolapsed disc, spinal manipulation.⁷ In our case patient was military personnel who had to undergo heave physical exercise.

However, migration of the herniated disc dorsally is one of the extremely rare conditions with the challenge in diagnosis. There are increasing unusual disc herniation cases report, which should make surgeon skeptical while diagnosing extradural spine pathology. However, early surgery is always the

treatment of choice to intercept further deterioration of neurological symptoms.

Consent: [JNMA Case Report Consent Form](#) was signed by the patient and the original article is attached to the patient's chart.

Conflict of Interest: None.

REFERENCES

- Spengler DM, Ouellette EA, Battie M, Zeh J. Elective discectomy for herniation of a lumbar disc. Additional experience with an objective method. *J Bone Joint Surg Am*. 1990 Feb;72(2):230-7. [[PubMed](#) | [Full Text](#)]
- Fardon DF. Nomenclature and classification of lumbar disc pathology. *Spine (Phila Pa 1976)*. 2001 Mar 1;26(5):461-2. [[PubMed](#) | [Full text](#) | [DOI](#)]
- Ebeling U, Reulen H. Are there typical localisations of lumbar disc herniations? A prospective study. *Acta Neurochir (Wien)*. 1992;117(3-4):143-8. [[PubMed](#) | [Full text](#) | [DOI](#)]
- Schellinger D, Manz HJ, Vidic B, Patronas NJ, Deveikis JP, Muraki AS, et al. Disk fragment migration. *Radiology*. 1990 Jun;175(3):831-6. [[PubMed](#) | [Full text](#) | [DOI](#)]
- Kim J-S, Lee S-H, Arbatti NJ. Dorsal extradural lumbar disc herniation causing cauda equina syndrome: a case report and review of literature. *J Korean Neurosurg Soc*. 2010 Mar;47(3):217-20. [[PubMed](#) | [Full text](#) | [DOI](#)]
- Lakshmanan P, Ahuja S, Lyons K, Howes J, Davies PR. Sequestered lumbar intervertebral disc in the posterior epidural space: a report on two cases and review of the literature. *Spine J*. 2006 Sep-Oct;6(5):583-6. [[PubMed](#) | [Full text](#) | [DOI](#)]
- Kuzeyli K, Çakir E, Usul H, Baykal S, Yazar U, Karaarslan G, et al. Posterior epidural migration of lumbar disc fragments: report of three cases. *Spine (Phila Pa 1976)*. 2003 Feb 1;28(3):E64-7. [[PubMed](#) | [Full text](#) | [DOI](#)]
- Teufack SG, Singh H, Harrop J, Ratliff J. Dorsal epidural intervertebral disk herniation with atypical radiographic findings: case report and literature review. *J Spinal Cord Med*. 2010;33(3):268-71. [[PubMed](#) | [Full text](#) | [DOI](#)]
- El Asri AC, Naama O, Akhaddar A, Gazzaz M, Belhachmi A, El Mostarchid B, et al. Posterior epidural migration of lumbar disk fragments: report of two cases and review of the literature. *Surg Neurol*. 2008 Dec;70(6):668-71. [[PubMed](#) | [Full text](#) | [DOI](#)]
- Dösoğlu M, Is M, Gezen F, Ziyal M. Posterior epidural migration of a lumbar disc fragment causing cauda equina syndrome: case report and review of the relevant literature. *Eur Spine J*. 2001 Aug;10(4):348-51. [[PubMed](#) | [Full text](#) | [DOI](#)]
- Wasserstrom R, Mamourian AC, Black JF, Lehman RA. Intradural lumbar disk fragment with ring enhancement on MR. *Am J Neuroradiol*. 1993 Mar-Apr;14(2):401-4. [[PubMed](#) | [Full text](#) | [DOI](#)]
- Coscia M, Leipzig T, Cooper D. Acute cauda equina syndrome. Diagnostic advantage of MRI. *Spine (Phila Pa 1976)*. 1994 Feb 15;19(4):475-8. [[PubMed](#) | [Full text](#) | [DOI](#)]
- Chen CY, Chuang YL, Yao MS, Chiu WT, Chen CL, Chan WP. Posterior epidural migration of a sequestered lumbar disk fragment: MR imaging findings. *Am J Neuroradiol*. 2006 Aug;27(7):1592-4. [[PubMed](#) | [Full Text](#)]

©The Author(s) 2018.

This work is licensed under a Creative Commons Attribution 4.0 International License. The images or other third party material in this article are included in the article's Creative Commons license, unless indicated otherwise in the credit line; if the material is not included under the Creative Commons license, users will need to obtain permission from the license holder to reproduce the material. To view a copy of this license, visit <http://creativecommons.org/licenses/by/4.0/>