

Vaginal Leiomyoma: A Case Report

Miki Shah,¹ Rachana Saha,¹ Niranjana KC²

¹Department of Obstetrics and Gynaecology, Kathmandu Medical College and Teaching Hospital, Sinamangal, Kathmandu, Nepal, ²Kathmandu Medical College and Teaching Hospital, Sinamangal, Kathmandu, Nepal.

ABSTRACT

Leiomyomas are common benign tumors of the uterus, affecting 20-30% of women of reproductive age group. But vaginal leiomyomas remain an uncommon entity with only about 300 reported cases. The first case was described in 1733. Only a few cases have been reported in Nepal to date. Tumors are thought to arise from Mullerian smooth muscle cells in the sub-epithelium of the vagina. Vaginal leiomyomas are usually situated in the anterior vaginal wall. Here, we report a case of a 48-year-old multipara who presented the outpatient department with the ultrasonographic report showing multiple uterine fibroids but was asymptomatic. A physical examination showed a mass in the right vaginal wall. Pervaginal removal of the tumor was performed and subsequent histopathology revealed a vaginal leiomyoma. Removal of the tumor by the vaginal route, wherever possible, with the subsequent histopathological examination, appears to be the optimum management plan.

Keywords: case report; leiomyoma; vagina.

INTRODUCTION

Vaginal tumors are rare and include papilloma, hemangioma, mucus polyp, and rarely leiomyoma. Vaginal leiomyomas remain an uncommon entity with only about 300 reported cases since the first detected case back in 1733 by Denys de Leyden.¹ So far, only a few cases has been reported in Nepal. These tumors arise most commonly from the anterior vaginal wall causing varied clinical presentations. They may or may not be associated with leiomyomas elsewhere in the body. We report a case of a 48-year-old multipara who presented the outpatient department with the ultrasonographic report showing multiple uterine fibroids but was asymptomatic.

CASE REPORT

A 48-year-old para three lady was presented to the outpatient department (OPD) with no complaint but a routine ultrasonography (USG) showed multiple fibroid uterus, largest measuring 1 x 1 cm at the fundus. On per speculum examination, a mass of 4 x 2 x 2 cm was seen on right vaginal wall. On Per-vaginal examination, uterus was bulky and fornices were free. A firm mass with a smooth surface was felt in right lateral vaginal wall. Therefore, a provisional diagnosis of vaginal leiomyoma was made. The patient was

counseled for surgery. Informed consent was taken for photography and publication.

Removal of mass was planned vaginally. A foley's catheter was introduced into the urethra. Vaginal mucosa was separated from the mass and the mass was enucleated which was sent for histopathological examination. Redundant tissue was cut and approximated. Gross examination of the mass revealed a 4 x 2 x 2cm, firm solid mass with a smooth outline. The cut section showed a whorled appearance (Figure 1).

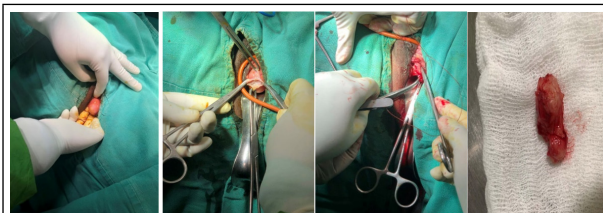


Figure 1. Intraoperative and postoperative pictures demonstrating removal of leiomyoma via vulvovaginal incision and its closure.

Correspondence: Dr. Miki Shah, Department of Obstetrics and Gynaecology, Kathmandu Medical College and Teaching Hospital, Sinamangal-9, Kathmandu, Nepal. Email: shahmiki73@gmail.com, Phone: +977-9851225463.

Microscopy revealed a circumscribed mass composed of smooth muscles arranged in intersecting bundles and fascicles without atypia, mitosis, and necrosis. Few dilated and congested vessels were also seen (Figure 2).

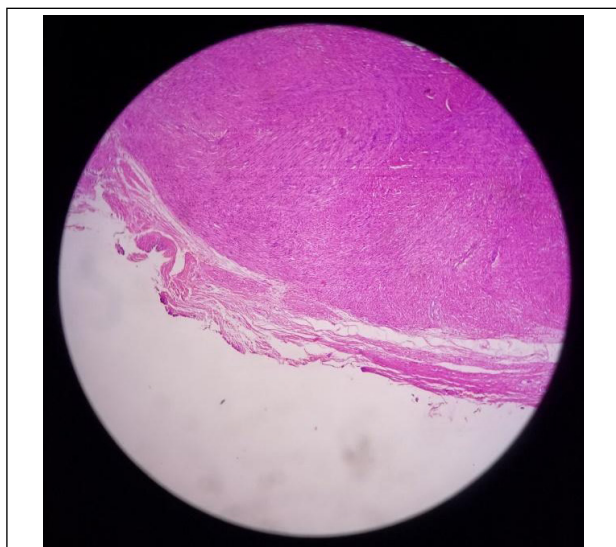


Figure 2. Vaginal tumor showing dense aggregation of spindle-shaped cells.

Her post-operative period was uneventful and she was discharged on the same day. On the 7th post-operative day, the patient was followed up at OPD with no complaints and the operation site was healthy.

DISCUSSION

Leiomyomas in the female genital tract are common in the uterus and to some extent in the cervix followed by the round ligament, uterosacral ligament, ovary, and inguinal canal.¹ Occurrence in the vagina is very rare. These tumors arise most commonly from the anterior vaginal wall causing varied clinical presentations.

REFERENCES

- Asnani M, Srivastava K, Gupta HP, Kunwar S, Srivastava AN. A rare case of giant vaginal fibromyoma. *Intractable Rare Dis Res.* 2016 Feb;5(1):44-6. [[PubMed](#) | [Full Text](#) | [DOI](#)]
- Bennett Jr HG, Ehrlich MM. Myoma of the vagina. *Am J Obstet Gynecol.* 1941 Aug 1;42(2):314-20. [[Full Text](#) | [DOI](#)]
- Shimada K, Ohashi I, Shibuya H, Tanabe F, Akashi T. MR imaging of an atypical vaginal leiomyoma. *AJR Am J Roentgenol.* 2002 Mar;178(3):752-4 [[PubMed](#) | [Full Text](#) | [DOI](#)]
- Elsayes KM, Narra VR, Dillman JR, Velcheti V, Hameed O, Tongdee R, et al. Vaginal masses: magnetic resonance imaging features with pathologic correlation. *Acta Radiol.* 2007 Oct;48(8):921-33. [[PubMed](#) | [Full Text](#) | [DOI](#)]
- Theodoridis TD, Zepiridis L, Chatzigeorgiou KN, Papanicolaou A, Bontis JN. Vaginal wall fibroid. *Arch Gynecol Obstet.* 2008 Sep;278(3):281-2. [[PubMed](#) | [Full Text](#) | [DOI](#)]
- Bapuraj JR, Ojili V, Singh SK, Prasad GR, Khandelwal N, Suri S. Preoperative embolization of a large vaginal leiomyoma: report of a case and review of the literature. *Australas Radiol.* 2006 Apr;50(2):179-82. [[PubMed](#) | [Full Text](#) | [DOI](#)]
- Cobanoglu O, Gurkan Zorlu C, Ergun Y, Kutluay L. Leiomyosarcoma of the vagina. *Eur J Obstet Gynecol Reprod Biol.* 1996 Dec 27;70(2):205-7. [[PubMed](#) | [Full Text](#) | [DOI](#)]

© The Author(s) 2018.

This work is licensed under a Creative Commons Attribution 4.0 International License. The images or other third party material in this article are included in the article's Creative Commons license, unless indicated otherwise in the credit line; if the material is not included under the Creative Commons license, users will need to obtain permission from the license holder to reproduce the material. To view a copy of this license, visit <http://creativecommons.org/licenses/by/4.0/>