

## Acute Conjunctivitis among Patients Visiting the Outpatient Department of Ophthalmology in a Tertiary Care Centre

Ram Shrestha,<sup>1</sup> Roshija Khanal Rijal,<sup>2</sup> Neyaz Kausar,<sup>3</sup> Oshan Shrestha,<sup>4</sup> Sagar Rajkarnikar,<sup>1</sup> Raina Chaudhary,<sup>5</sup> Kabindra Lal Shrestha,<sup>4</sup> Sitaram Khadka<sup>6</sup>

<sup>1</sup>Department of Ophthalmology, Shree Birendra Hospital, Chhauni, Kathmandu, Nepal, <sup>2</sup>Department of Ophthalmology, Shreekrishna Netralaya, Rudrapath, Bhairahawa, Nepal, <sup>3</sup>Department of Ophthalmology, Nepal Eye Hospital, Tripureswor, Kathmandu, Nepal, <sup>4</sup>Nepalese Army Institute of Health Sciences, Sanobharyang, Kathmandu, Nepal, <sup>5</sup>Department of Microbiology, Nepalese Army Institute of Health Sciences, Sanobharyang, Kathmandu, Nepal, <sup>6</sup>Health Service Division, Shree Birendra Hospital, Chhauni, Kathmandu, Nepal.

### ABSTRACT

**Introduction:** Conjunctivitis is a highly prevalent ocular disease that flares up every year. The humidity and high temperature favour the causative agents responsible for the epidemic. Acute infective conjunctivitis may be either viral or bacterial, a distinct type of condition with unique clinical features and treatment approaches. The aim of the study was to find out the prevalence of acute conjunctivitis among patients visiting the outpatient Department of Ophthalmology in a tertiary care centre.

**Methods:** This descriptive cross-sectional study was conducted among the patients visiting the outpatient Department of Ophthalmology. Data of 30 August 2023 to 30 September 2023 was collected between 21 November 2023 to 24 November 2023. All patients presenting in the Ophthalmology Department having complete hospital record were included in the study. Patients having missing data on the medical records of the hospital were excluded. A convenience sampling method was used. The point estimate was calculated at a 95% Confidence Interval.

**Results:** Among 5,507 patients, acute conjunctivitis was seen in 1240 (22.52%) (21.42-23.62, 95% Confidence Interval). The majority were male 732 (59.03%) and adults 760 (61.29%) with a mean age of 32.56±18.74 years.

**Conclusions:** The prevalence of conjunctivitis among patients visiting the outpatient Department of Ophthalmology was found to be higher than other studies done in similar settings.

**Keywords:** conjunctivitis; disease outbreaks; enterovirus.

### INTRODUCTION

Conjunctivitis is the most prevalent ocular disease occurring globally.<sup>1</sup> Acute infective conjunctivitis may be either viral or bacterial. According to the onset and the clinical response, viral conjunctivitis may be categorised into acute, hyperacute, and chronic types.<sup>2</sup>

While most bacterial conjunctivitis are self-limiting types with mucopurulent discharge, some cases have the potential for ocular morbidity.<sup>3</sup> Although self-limiting, antimicrobial therapy has shown clinical effectiveness, which has reduced distress, symptoms, duration, and contagious spread.<sup>4,5</sup> Adenovirus affects the conjunctiva and cornea as well, while enterovirus has more effects on the conjunctiva.

The aim of the study was to find out the prevalence of acute conjunctivitis among patients visiting the outpatient Department of Ophthalmology in a tertiary care centre.

### METHODS

A descriptive cross-sectional study was conducted in the outpatient Department of Ophthalmology at Shree Birendra Hospital (SBH). Ethical approval was

**Correspondence:** Dr Sitaram Khadka, Health Service Division, Shree Birendra Hospital, Chhauni, Kathmandu, Nepal. Email: sitaram.khadka@naihs.edu.np, Phone: +977-9851077589.

received from the Institutional Review Committee (Reference number: 245). Data of 30 August 2023 to 30 September 2023 was collected between 21 November 2023 to 24 November 2023. All patients presenting in the Ophthalmology Department having complete hospital record were included in the study. Patients with missing data on the medical records of the hospital were excluded. A convenience sampling method was used. The sample size was calculated using the following formula:

$$n = Z^2 \times \frac{p \times q}{e^2}$$

$$= 1.96^2 \times \frac{0.50 \times 0.50}{0.02^2}$$

$$= 2,401$$

Where,

n = minimum required sample size

Z = 1.96 at 95% Confidence Interval (CI)

p = prevalence taken as 50% for maximum sample size calculation

q = 1-p

e = margin of error, 2%

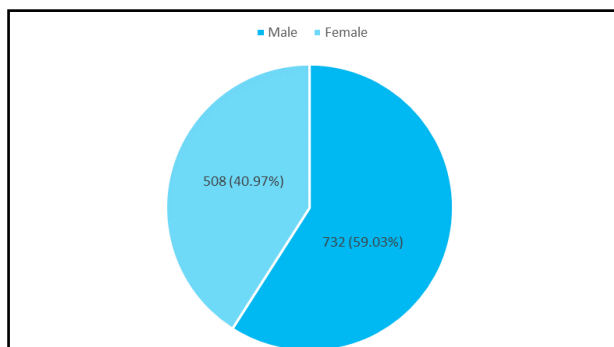
The calculated sample size was 2,401. As the convenience sampling method was used, the sample was doubled and became 4,802. However, 5,507 patients were included in the study.

Demographic details, clinical signs and symptoms of the patients, and co-morbidities were noted.

Data were entered and analyzed using IBM SPSS Statistics version 21.0. The point estimate was calculated at a 95% CI.

## RESULTS

Out of 5507 patients, 1,240 (22.52%) (21.42-23.62, 95% CI) presented with acute conjunctivitis. It was more predominant in male 732 (59.03%) (Figure 1).



**Figure 1. Gender-wise distribution of patients with conjunctivitis (n= 1240).**

The mean age of patient was  $32.56 \pm 18.74$  years. The majority of the patients were residents of Kathmandu

district 910 (73.39%), followed by Bhaktapur and Lalitpur districts (Table 1).

**Table 1. Demographic evaluation of the patients (n= 1240).**

Variables	n (%)	
Age group (years)	0-17	380 (30.65)
	18-59	760 (61.29)
	$\geq 60$	100 (8.06)
Location	Kathmandu	910 (73.39)
	Bhaktapur	217 (17.50)
	Lalitpur	113 (9.11)

The most frequent presenting complaints after red eye were redness, eye swelling, watering, discharge, and discomfort. On clinical evaluation, congestion was present among all the cases whereas serous exudate, follicle, lid swelling, and chemosis were mostly found on examination.

## DISCUSSION

The prevalence of acute conjunctivitis in our study was 1,240 (22.52%) which is higher compared to a similar previous study where the prevalence was 8.1%.<sup>6</sup> Similarly, the prevalence of conjunctivitis in our study is higher than a study previously conducted in Kolkata with a prevalence of 17.23%.<sup>7</sup> The prevalence might have been higher due to the epidemic of conjunctivitis at the time of the study. This descriptive study had a representation of patients of all age groups and both sexes.

Conjunctivitis is also referred to as pink eye,<sup>8</sup> which concurs with the findings of our study. Redness, eye swelling, watering, discomfort, and discharge were symptoms with a higher frequency in this study, which is also supported by the findings of a systematic review.<sup>9</sup> Conjunctivitis can be caused by various factors, leading to distinct types of conditions, each with unique causes, clinical features, and treatment approaches.<sup>10</sup>

The first manifestation of a viral infection may be conjunctivitis, which can also be the only manifestation.<sup>11</sup> A papillary conjunctival reaction, or pseudomembranous conjunctivitis, strongly suggests a bacterial origin for conjunctivitis, while a follicular conjunctival reaction is more likely to indicate a viral cause. Viral conjunctivitis is the most common overall cause of infectious conjunctivitis, which often starts suddenly and can be highly contagious, resulting in outbreaks, especially in crowded settings.<sup>8,12</sup>

Enterovirus multiplies in the intestines and spreads through respiratory secretions, faeces, and

contaminated water. A study has also reported an association between the quality of the water supply and enterovirus infection.<sup>13,14</sup> With this in mind, the role of the water supply in Kathmandu Valley in the outbreak may be the subject of further study. Overcrowding, poorer ventilation of the accommodation, and lesser body immunity might be other parameters that had affected the disease and the outcome.

After viral aetiology, bacterial conjunctivitis is commonly encountered. The most common pathogens for bacterial conjunctivitis in adults are staphylococcal species.<sup>15</sup> Bacterial conjunctivitis has a course of 1-2 weeks, and its presentation includes features like redness of the eye, chemosis, and mucopurulent discharge. Bacterial conjunctivitis can be differentiated from viral conjunctivitis through the clinical features, but one can always benefit from the testing kits.<sup>8</sup> It is necessary to differentiate bacterial from viral causes to avoid unnecessary antibiotic use.

The medical intervention aims primarily at

controlling the large outbreaks as well as instituting preventative measures to protect vulnerable groups, such as children, the elderly, pregnant women, and immunocompromised individuals, by encouraging frequent hand-washing and reducing contact with the affected individuals. Restriction of touching the eyes with infected hands helps to prevent and reduce the flaring up of the disease.<sup>12</sup>

This is a single-centre study with a limited sample size and duration. Moreover, the limitation in quota regarding the opportunity of virus detection facilities with PCR testing and the availability of PCR kits in low- and middle-income countries like Nepal was a big limitation in generalizing the findings of the study.

## CONCLUSIONS

The prevalence of acute conjunctivitis among patients visiting the Department of Ophthalmology was found to be higher than other studies done in similar settings.

**Conflict of Interest: None.**

## REFERENCES

- Adebayo A, Parikh JG, McCormick SA, Shah MK, Huerto RS, Yu G, et al. Shifting trends in in vitro antibiotic susceptibilities for common bacterial conjunctival isolates in the last decade at the New York Eye and Ear Infirmary. *Graefes Arch Clin Exp Ophthalmol*. 2011 Jan;249(1):111-9. [[PubMed](#) | [Full Text](#) | [DOI](#)]
- Hovding G. Acute bacterial conjunctivitis. *Acta Ophthalmol*. 2008 Feb;86(1):5-17. [[PubMed](#) | [Full Text](#) | [DOI](#)]
- Shrestha SP, Khadka J, Pokhrel AK, Sathian B. Acute bacterial conjunctivitis - antibiotic susceptibility and resistance to commercially available topical antibiotics in Nepal. *Nepal J Ophthalmol*. 2016 Jan;8(15):23-35. [[PubMed](#) | [Full Text](#) | [DOI](#)]
- Hutnik C, Mohammad-Shahi MH. Bacterial conjunctivitis. *Clin Ophthalmol*. 2010 Dec 6;4:1451-7. [[PubMed](#) | [Full Text](#) | [DOI](#)]
- Tarabishy AB, Jeng BH. Bacterial conjunctivitis: a review for internists. *Cleve Clin J Med*. 2008 Jul;75(7):507-12. [[PubMed](#) | [DOI](#)]
- Basnet PS, Malla S, Sharma D, Gautam R. Clinical profile of ocular diseases at a tertiary eye care centre in mid-western Nepal. *Nepalese Medical Journal*. 2021;4:439-41. [[Full Text](#) | [DOI](#)]
- Pippin MM, Le JK. Bacterial conjunctivitis. 2023 Aug 17. In: *StatPearls* [Internet]. Treasure Island (FL): StatPearls Publishing; 2023 Jan. Available from: <https://www.statpearls.com/point-of-care/19891>. [[Full Text](#)]
- Azari AA, Barney NP. Conjunctivitis: a systematic review of diagnosis and treatment. *Jama*. 2013 Oct 23;310(16):1721-9. [[PubMed](#) | [Full Text](#) | [DOI](#)]
- Muto T, Imaizumi S, Kamoi K. Viral conjunctivitis. *Viruses*. 2023 Mar 4;15(3):676. [[PubMed](#) | [Full Text](#) | [DOI](#)]
- Biswas J, Saha I, Das D, Bandyopadhyay S, Ray B, Biswas G. Ocular morbidity among children at a tertiary eye care hospital in Kolkata, West Bengal. *Indian J Public Health*. 2012 Oct-Dec;56(4):293-6. [[PubMed](#) | [Full Text](#) | [DOI](#)]
- Ozturker ZK. Conjunctivitis as sole symptom of COVID-19: a case report and review of literature. *Eur J Ophthalmol*. 2021 Mar;31(2):NP161-6. [[PubMed](#) | [Full Text](#) | [DOI](#)]
- Centers for Disease Control and Prevention. Conjunctivitis (Pink Eye) [Internet]. Atlanta (US): CDC; 2021 Nov 12 [Cited 2023 Oct 10]. Available from: <https://www.cdc.gov/conjunctivitis/index.html>. [[Full Text](#)]
- Hamaguchi T, Fujisawa H, Sakai K, Okino S, Kurosaki N, Nishimura Y, et al. Acute encephalitis caused by intrafamilial transmission of enterovirus 71 in adult. *Emerg Infect Dis*. 2008 May;14(5):828-30. [[PubMed](#) | [Full Text](#) | [DOI](#)]
- Joshi YP, Kim JH, Kim H, Cheong HK. Impact of drinking water quality on the development of enteroviral diseases in Korea. *Int J Environ Res Public Health*. 2018 Nov 14;15(11):2551. [[PubMed](#) | [Full Text](#) | [DOI](#)]
- Epling J, Smucny J. Bacterial conjunctivitis. *Clin Evid*. 2005 Dec;(14):756-61. [[PubMed](#)]

© The Author(s) 2024.

This work is licensed under a Creative Commons Attribution 4.0 International License. The images or other third party material in this article are included in the article's Creative Commons license, unless indicated otherwise in the credit line; if the material is not included under the Creative Commons license, users will need to obtain permission from the license holder to reproduce the material. To view a copy of this license, visit <https://creativecommons.org/licenses/by/4.0/>