ORIGINAL ARTICLE

Clinico-Pathological Characteristics of GIST of Stomach along with Evaluation of their Immunohistochemical Features

Udaya Koirala[1], Sharmila Parajuli[2]

ABSTRACT

Introduction: Gastrointestinal stromal tumors (GISTs) are the most common neoplasms and they originate in the interstitial cells of Cajal. Determining morphological and immunohistochemical features remains paramount in the diagnostic approach to patients with GIST suspicion. The most common histopathological subtype is the spindle cell type followed by epithelioid cell type. Current important immunohistochemical panel for GIST includes CD117, DOG-1, SMA and CD34; with CD117 (C-Kit) being the most sensitive and specific marker for GIST.

Methods: We studied 31 cases of GIST of stomach diagnosed in combined Haemotoxylin and Eosin and immunohistochemistry. Immunohistochemistry for Ki-67 (Proliferative index) along with CD 117, DOG-1 and CD34 were evaluated and the results were recorded.

Results: The age group ranged from 40 year to 80 years with an average of 53 years. Out of the 31 cases; the male to female ratio was 1.3:1. The average diameter of the tumor was 8.7cm. On histological examination; spindle cell pattern was the most common accounting for 77.41% of the cases followed by epithelioid pattern accounting for 11.90% of the cases. Most of the cases showed positivity for CD117; 27 cases (87.09%). 4 cases (12.90%) which were CD 117 negative showed positivity for DOG-1. CD34 was seen in 45% of the cases.

Conclusion: The commonest histomorphological pattern was spindle cell pattern accounting for 77.41% of the cases. C-Kit immunostaining showed positivity in 87.09 % of the tumors in this study. The immunohistochemical results in our study on stomach GIST are comparable to both local and international studies.

Keywords: CD 117 (C-kit), DOG -1 (Discovered on GIST 1), GIST (Gastrointestinal stromal tumors), H and E (Haemotoxylin and Eosin),

INTRODUCTION

GISTs are one of the commonest mesenchymal tumors of gastrointestinal tracts occurring from esophagus to rectum with stomach being most commonly affected.[1] The cell of origin in GISTs is interstitial cell of Cajal, which acts as pacemaker by creating electrical rhythm for peristalsis, present in muscularis propria and submucosa.[2]

Symptoms that lead to the diagnosis of GIST are often vague, such as abdominal pain, bloating, anorexia,

[1]Department of General Surgery, Kathmandu Model Hospital-Institute of Health Sciences (KMH-IHS), Exhibition road, Kathmandu, Nepal

[2]Department of Pathology, Kathmandu Model Hospital-Institute of Health Sciences (KMH-IHS), Exhibition road, Kathmandu, Nepal

***Corresponding author**

Dr. Udaya Koirala, Department of General Surgery, Kathmandu Model Hospital-Institute of Health Sciences (KMH-IHS), Exhibition road, Kathmandu, Nepal, Phone: +9779841339136, Email: udaykoirala@hotmail.com

regurgitation and weight loss.[3] GIST has been divided into mainly three types- spindle cell type, epithelioid cell type and mixed cell type with spindle cell type accounting for 70% of the cases.[4]

The most common associated antibodies are CD117, Dog-1 and CD34.[5] Although CD117 positivity has traditionally been seen as the gold standard for GIST diagnosis and, at least in early clinical trials, as an eligibility criterion for imatinib therapy[6], about 4–10% of GISTs express little or no CD117.[7-9] Today, it is widely accepted that CD117-negative GISTs are a heterogenous group of neoplasms that frequently display mutations and may also express DOG-1.[10] Here, we evaluated the expression of immunohistochemical markers like proliferative index (Ki-67), CD117, DOG-1, CD34 in the tumor cells.

METHODS

This is a retrospective study conducted in Kathmandu Model Hospital from January 2016- December 2023. 31 cases of GIST of stomach diagnosed in combined H and E and immunohistochemistry were included in the study. Hospital records were retrieved for clinical details including the clinical presentation, age, gender and tumor size. All the specimens were fixed in 10% formalin overnight and processed in an auto-tissue processor. The sections were made with microtome and stained with hematoxylin and eosin stain. (H & E stain). The histopathological features such as morphology including spindle, epithelioid and mixed type were evaluated. Immunohistochemical expression of Ki-67 (Proliferative index) along with CD 117, DOG-1 and CD34 were detected by applying immunohistochemical marker on formalin fixed and paraffin embedded representative tumor sections. Patients who received prior targeted chemotherapy were excluded from the study. Data was analysed by using computer software program SPSS version 20. Mean and standard deviation was calculated for age of the patient and size of the tumour. Frequencies and percentages were calculated for gender, tumor size, histological subtype, proliferative index (Ki-67) and immunohistochemistry for CD 117, DOG1 and CD34.

RESULTS

The majority of the patients were in-between the age groups of 50-60 years- 15 cases (48.38%). The least number of cases were in-between the age groups of 70-80 years- 04 cases (12.90%). The mean age in our study was 53 years.

Table 1: Age distribution of patients (n=31)

Age (years)	Percentage
40-50	5 (16.1%)
50-60	15 (48.38%)
60-70	7 (22.58%)
70-80	4 (12.90%)
TOTAL	31 (100%)

Table 2: Clinicopathological characteristics of patients with gastric GISTs (n=31)

Clinical Characteristics	Total number (n=31) %
Gender	
Male	18
Female	13
Tumor size (cm) Mean	8.7
Morphology (H&E)	
Spindle cell	24 (77.41%)
Epitheloid	4 (11.90%)
Mixed	3 (9.68%)

The male to female ratio was 1.3:1. The mean tumor size was 8.7cm. The commonest histological pattern was the spindle cell type acconting for a total of 24cases (77.41%)

Table 3: Showing positivity of Ki-67 (Proliferative index)

Ki-67 staining	Percentage Positivity
Low- <5%	25 (80.65%)
High - >20%	6 (19.35%)

Ki-67 immunoexpression were low in 25 (82.65%) cases and high in 6 cases (19.35%)

Table 4: Showing positive immunohistochemical panel

Immunohistochemistry panel	Percentage Positivity
CD 117	20 (86.25%)
Dog 1	3 (13.04%)
CD34	11 (47.8%)

CD117 immunostaining showed diffuse positivity in 20 cases (86.25%).

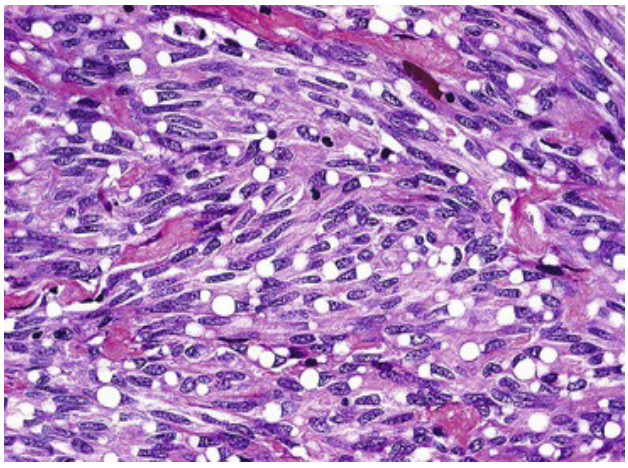

Figure 1. Gastrointestinal stromal tumors- Spindle cell variant showing spindled cells in fascicles with plump to elongated nuclei and eosinophilic cytoplasm (H &E X40)

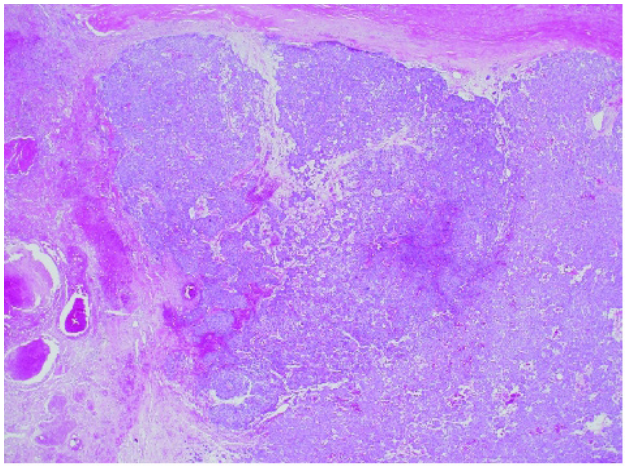

Figure 2. Highly aggressive tumor cells forming a demarcated area of necrosis and Hemorrhage (H &E X10)

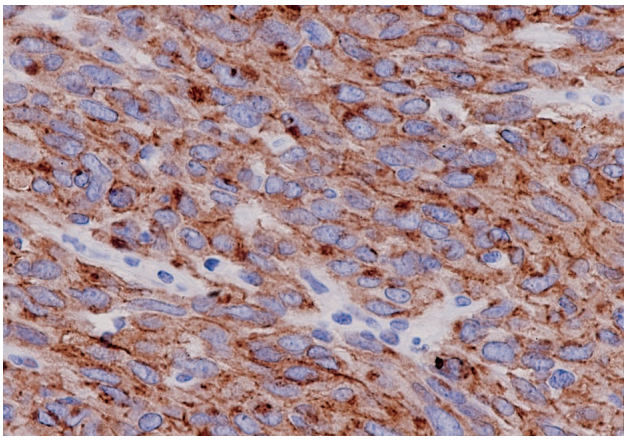

Figure 3. Gastrointestinal stromal tumors; CD117 shows diffuse cytoplasmic staining with membranous accentuation

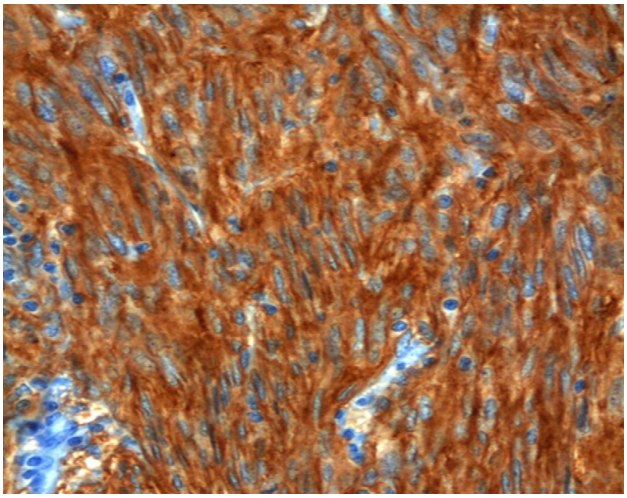

Figure 4. Gastrointestinal stromal tumors; DOG-1 shows intense cytoplasmic staining

DISCUSSION

GISTs account for only 1-3% of all cases of gastrointestinal tumors but they are most frequent cause of mesenchymal tumors of gastrointestinal tract. They are distinct subset of tumors due to the presence of oncogenic mutations of KIT detected by CD-117 immunohistochemical antibody. In an era, prior to advent of targeted therapy (imatinib) against KIT mutation, GISTs carried dismal prognosis due to their resistance to chemo and radiotherapy. The mean age in our study was 53 years with highest number of cases seen in 5th and 6th decade. The mean age in our study is slightly lower than reported in western and Asian

literature, where the mean age has been reported from 56 to 65 years[11, 12]

There was a slight male predominance in our study with male to female ratio of 1.3:1. This is also supported by few studies[11, 13, 14]; however various studies showed no gender predilection. In our study the average tumor size was 8.7cm, more as compared to previous study on gastric GISTs in which mean tumor size was 6cm and nearly equal to a local study by Nasir et al.[13,14]

Histological findings in our study showed spindle cell morphology in 24 cases (77.41%); whereas only 4 cases were epitheloid type (11.90%). International studies revealed a high percentage of epitheloid variant of GISTs, however a local study in 2015 showed same results.[13-16]

Immunohistochemically, CD117 was the most helpful antibody, being diffuse positive in almost 86.25%. It not only aids in diagnosis but also detects underlying c KIT mutation[15,17]. DOG1 demonstrated diffuse positivity in all the CD 117 negative cases (13.04%). Our study was comparable with Leigl B in which they found DOG-1 as sensitive and specific for GISTs with additional advantage of detecting KIT negative GISTs.[18] Western literature showed same results in which CD117 positivity was seen in 95% gastric GISTs.

CONCLUSION

The clinical presentation of GIST are highly variable. Simultaneous assessment of clinicomorphological characteristic and immunohistochemical features at the time of initial diagnosis, not only determine the risk stratification in GISTs patients but they also carry therapeutic implication where targeted therapies are being offered.

REFERENCES

1. Zhao X, Yue C. Gastrointestinal stromal tumor. Journal of gastrointestinal oncology. 2012 Sep;3(3):189. [PubMed]
2. Koumarianou A, Economopoulou P, Katsaounis P, Laschos K, Arapantoni-Dadioti P, Martikos G, et al. Gastrointestinal Stromal Tumors (GIST): A Prospective Analysis and an Update on Biomarkers and Current Treatment Concepts: Supplementary Issue: Biomarkers for Colon Cancer. Biomarkers in cancer. 2015 Jan;7:BIC-S25045. [DOI] [Full Text]
3. Eisenberg BL, Pipas JM. Gastrointestinal stromal tumor—background, pathology, treatment. Hematology/Oncology Clinics. 2012 Dec 1;26(6):1239-59. [Full Text]
4. Nishida T, Blay JY, Hirota S, Kitagawa Y, Kang YK. The standard diagnosis, treatment, and follow-up of gastrointestinal stromal tumors based on guidelines. Gastric cancer. 2016 Jan;19:3-14. [Full Text]
5. Mantese G. Gastrointestinal stromal tumor: epidemiology, diagnosis, and treatment. Current opinion in gastroenterology. 2019 Nov 1;35(6):555-9. [PubMed]
6. Fletcher CD, Berman JJ, Corless C, Gorstein F, Lasota J, Longley BJ, et al. Diagnosis of gastrointestinal stromal tumors: a consensus approach. International journal of surgical pathology. 2002 Apr;10(2):81-9. [Full Text]
7. Medeiros F, Corless CL, Duensing A, Hornick JL, Oliveira AM, Heinrich MC, et al. KIT-negative gastrointestinal stromal tumors: proof of concept and therapeutic implications. The American journal of surgical pathology. 2004 Jul 1;28(7):889-94. [Full Text]
8. Miettinen M, Sobin LH, Sarlomo-Rikala M. Immunohistochemical spectrum of GISTs at different sites and their differential diagnosis with a reference to CD117 (KIT). Modern pathology. 2000 Oct 1;13(10):1134-42. [DOI]
9. Miettinen M, Lasota J. Gastrointestinal stromal tumors–definition, clinical, histological, immunohistochemical, and molecular genetic features and differential diagnosis. Virchows archiv. 2001 Jan;438:1-2. [Full Text]
10. Kang GH, Srivastava A, Kim YE, Park HJ, Park CK, Sohn TS, et al. DOG1 and PKC-θ are useful in the diagnosis of KIT-negative gastrointestinal stromal tumors. Modern pathology. 2011 Jun 1;24(6):866-75. [PubMed]
11. Salari M, Ahadi M, Hoseini SM, Mokhtari E, Gafarzadehgan K, Hashemian HR, et al. Gastrointestinal stromal tumors in Northeastern Iran: 46 cases during 2003-2012. Middle East Journal of Digestive Diseases. 2015 Jul;7:161. [PubMed]
12. Cyriac S, Rajendranath R, Sagar TG. Gastrointestinal stromal tumor: Analysis of outcome and correlation with c-kit status in Indian population. Indian Journal of Cancer. 2014 Jan 1;51(1):S35-39. [PubMed]
13. Miettinen M, Sobin LH, Lasota J. Gastrointestinal

stromal tumors of the stomach: a clinicopathologic, immunohistochemical, and molecular genetic study of 1765 cases with long-term follow-up. The American journal of surgical pathology. 2005 Jan 1;29(1):52-68. [PubMed]

14. Ud Din N, Ahmad Z, Arshad H, Idrees R, Kayani N. Gastrointestinal stromal tumors: a clinicopathologic and risk stratification study of 255 cases from Pakistan and review of literature. Asian Pacific Journal of Cancer Prevention. 2015;16(12):4873.[PubMed]

15. Baskin Y, Kocal GC, Kucukzeybek BB, Akbarpour M, Kayacik N, Sagol O, et al. PDGFRA and KIT mutation status and its association with Clinicopathological properties, including DOG1. Oncology Research. 2016;24(1):41.[PubMed]

16. Rosai J. Rosai and Ackerman's surgical pathology. 10th ed. New York: Elsevier; 2012.

17. Hornick JL, Fletcher CD. The role of KIT in the management of patients with gastrointestinal stromal tumors. Human pathology. 2007 May 1;38(5):679-87. [PubMed]

18. Liegl B, Hornick JL, Corless CL, Fletcher CD. Monoclonal antibody DOG1. 1 shows higher sensitivity than KIT in the diagnosis of gastrointestinal stromal tumors, including unusual subtypes. The American journal of surgical pathology. 2009 Mar 1;33(3):437-46.[PubMed]